



ISSN:2456-9739

Available Online at <http://www.bjbmr.org>

BRITISH JOURNAL OF BIO-MEDICAL RESEARCH

Cross Ref DOI: <https://doi.org/10.24942/bjbmr.2022.919> Volume 06, Issue 01, Jan - February 2022

Research Article

'Porpillage' And 'Torpillage'- Innovative Techniques In Ossicular Reconstruction

Dr. Nilam U Sathe¹, Dr. Suraj Nair², Dr. Dhanashree Chiplunkar³, Dr. Kamini Chavan⁴

¹Head of Unit and Associate Professor, Department of ENT, KEM Hospital, Mumbai

²Senior Resident, Department of ENT, KEM Hospital, Mumbai

³Assistant Professor, Department of ENT, KEM Hospital, Mumbai

⁴Senior Resident, Department of ENT, KEM Hospital, Mumbai

ARTICLE INFO

Article History:

Received on 06th Jan 2022

Peer Reviewed on 19th Jan 2022

Revised on 14th February 2022

Published on 27th February 2022

Keywords:

P Ossiculoplasty, cartilage, PORP, TORP.

ABSTRACT

Introduction- Titanium prostheses provide functionally promising results after reconstruction. Additional designs are created to improve and facilitate the surgical technique. The aim of our prospective observational study was to evaluate the functional results using the assembly of PORP or TORP with cartilage sutured together during ossiculoplasty.

Material & method- Our technique for ossiculoplasty lies in the principle of providing cartilage support for the PORP or TORP in order to keep the assembly stable and secure during the post-operative recovery time thus ascertaining the reduction in the number of prosthesis displacement or extrusion cases. PORP or TORP and cartilage assembly is sutured with 3-0 vicryl suture.

Conclusion- Teflon prosthesis is a very versatile and compatible material for ossiculoplasty with less wear and tear and it remains in place for several weeks. Suturing the cartilage with PORP or TORP using vicryl suture keeps the assembly in position during the first few weeks till the healing is complete. TORP/PORP cartilage assembly with vicryl sutures prevents long term hazards of foreign body granulomatous reaction in the middle ear. As well as there are less chances of prostheses extrusion & expected to result in better post-operative hearing outcomes.

Br J Bio Med Res Copyright©2022 Dr. Nilam U Sathe et al. This is an Open Access article distributed under the terms of the Creative Commons Attribution 4.0 International License (<http://creativecommons.org/licenses/by/4.0/>), allowing third parties to copy and redistribute the material in any medium or format and to remix, transform, and build upon the material for any purpose, even commercially, provided the original work is properly cited and states its license.

Corresponding Author: Dr. Nilam U Sathe. NJ, Associate Professor, Dept. of ENT and Head – Neck Surgery, Seth G. S. Medical College and KEM Hospital. Parel. Mumbai - 400 012.

INTRODUCTION

The field of otology has been always curious to accept and modify the various techniques in reconstructing the middle ear conductive mechanism. Ever since Matte's first myringo-stapedioplasty in 1901, there have been sincere attempts for providing the patient with better post-operative hearing (1,2). Ossiculoplasty is defined as restoring the hearing mechanism between the tympanic membrane and the oval window by re-establishing a functioning ossicular chain. It is indicated both mucosal and squamosal type of chronic otitis media leading to ossicular discontinuity, ossicular fixation due to tympanosclerosis, adhesions etc. Trauma to the middle ear ossicles either iatrogenic or otherwise is also a leading cause for ossiculoplasty. Operating on an only hearing ear is an absolute contraindication for ossiculoplasty.

The plethora of ossicular prostheses available in recent times is an obvious proof of the depth of ongoing research in this field. The ultimate aim is to develop a prosthesis which could reproduce and perhaps improve upon the natural impedance matching system at vital hearing frequencies in a consistent manner (3,4). Initially, autografts and allografts were the ossicular replacement material used most commonly by otologists. However, owing to the risk of prion disease (including Creutzfeldt-Jakob disease) transmission, use of allografts have come to a near halt. The advent of various bio-inert compatible prosthetic materials with better stability and hearing outcomes have shifted the balance in favour of prosthetic implants over last few decades (3). The new age otologist has a wide array of middle ear implants to choose from but finds it difficult to know which one works best.

Optimal results in ossicular reconstruction depend not only on the qualities of the prosthesis, but also on the environment in which it is placed and the surgical techniques used. There are controversial reports in literature regarding the use of each of the various prostheses with generous consideration given to the middle ear status and stability of

the reconstruction. Many of the studies preferred methods utilizing the patient's own tissue but when the situation is feasible, prosthetic devices have also given good results(5).

Prosthetic devices are classified according to the desired reconstruction:

- Incus prostheses: when the malleus and stapes are present.
- Incus-stapes prostheses : when the stapes footplate is present along with an intact malleus.
- Partial ossicular replacement prostheses (PORPs): when the stapes superstructure is intact.
- Total ossicular replacement prostheses (TORPs) : when only the stapes footplate is available.(4,5).

The stability of the titanium prosthesis is always under debate leading to doubtful consistent post-operative hearing. A small piece of cartilage is considered mandatory to be placed over the PORP or TORP to provide stability and to prevent extrusion of the prosthesis(6,7). In our study we have tried to improve the stability of the PORP or TORP with cartilage assembly by suturing them with vicryl suture.

MATERIAL AND METHODS

Surgical technique :

All the patients in our study were cases of chronic otitis media both mucosal and squamosal type with pre-operative conductive hearing loss. Depending on the nature of the disease process and extent of mastoid bone involved, patients underwent canal wall down or down type of mastoidectomy with posterior canal wall reconstruction in some cases. After the completion of mastoidectomy with clearance of disease, the ossicular integrity was assessed and a decision regarding the type of ossicular reconstruction and material was taken. Partial ossicular reconstruction prosthesis (PORP) was used in the presence of an intact stapes suprastructure and Total ossicular reconstruction prosthesis (TORP) was

used when only the stapes footplate was available.

Our technique for ossiculoplasty lies in the principle of providing cartilage support for the PORP or TORP in order to keep the assembly stable and secure during the post-operative recovery time thus ascertaining the reduction in the number of prosthesis displacement or extrusion cases. This is brought about by procuring a small piece of conchal or tragal cartilage about 0.5*0.5 cm size and placed in normal saline (Figure1, 2).

Once the mastoid clearance of disease is completed, temporalis fascia graft is placed and adjusted in position. The graft and the tympanomeatal flap are then gently elevated to expose the ossicular remnants like the stapes suprastructure or footplate. This forms the receptive bed for the assembly to be placed for reconstruction. PORP or TORP is held gently with ossicle holding forceps and the harvested

cartilage is held with small artery forceps (Figure 3 a, 3b). 3-0 vicryl suture is passed through both the components of the assembly (Figure 4) and knots applied with slow and delicate wrist movements (Figure 5 a, b, c & Figure 6 a, b). PORP or TORP and cartilage assembly is placed in the receptive bed and adjusted in order to lie as vertically as possible contacting the temporalis graft and malleus if possible. The vertical positioning of the assembly provides adequate height to the middle ear which has an effect on post-operative hearing outcomes. The assembly provides a secure hold on the cartilage over the prosthesis in order to avoid any contact or friction between the prosthesis and graft. Such contact would be detrimental in causing extrusion of the prosthesis. Hence, this assembly provides more stability to the prosthesis. The surgery is completed with posterior canal reconstruction in some cases.

FIGURES

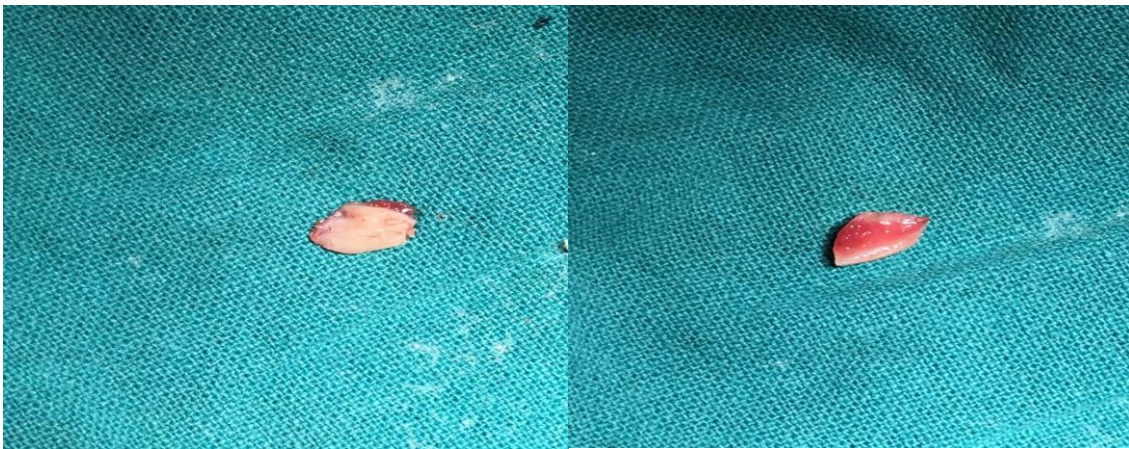

Figure .2

Figure. 1

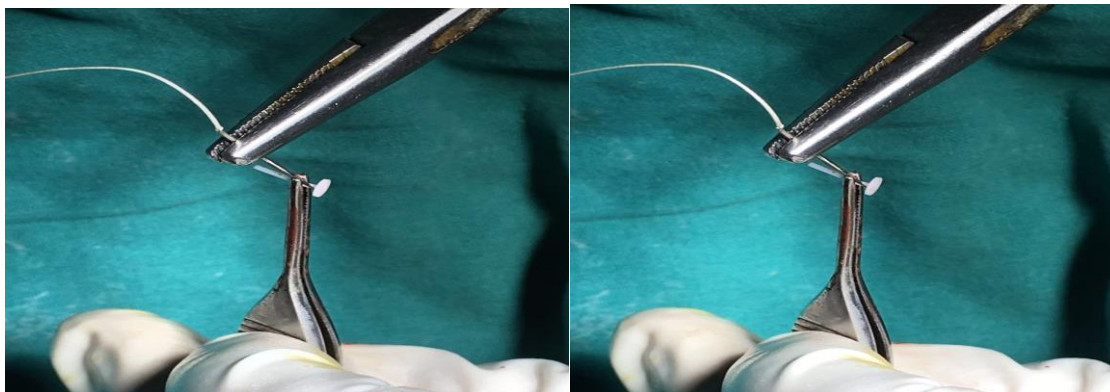


Figure. 3 a

Figure. 3 b

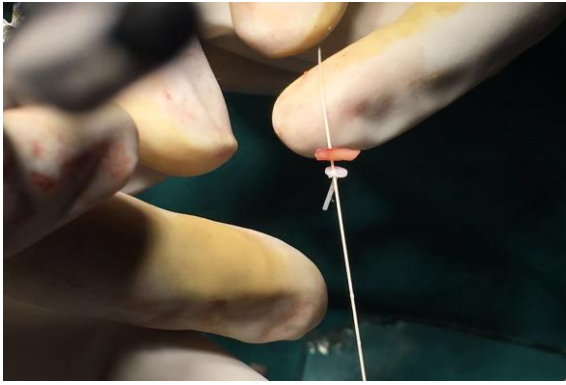


Figure.4

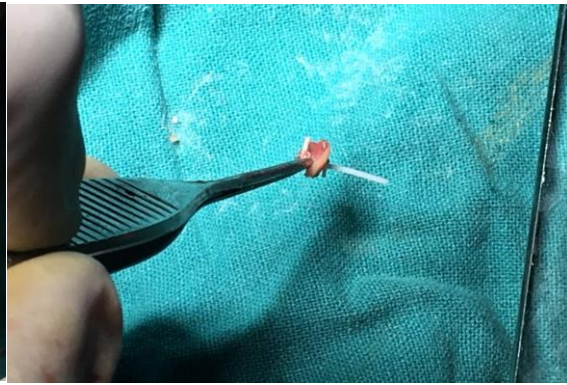

Figure 5 a

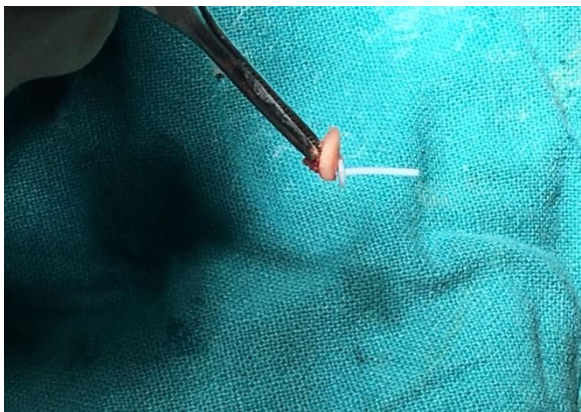

Figure 5 b

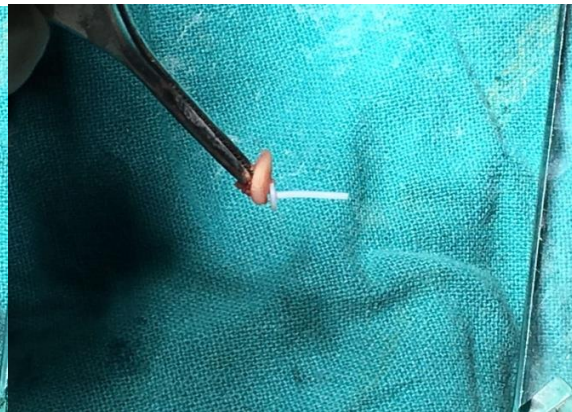


Figure 5 c

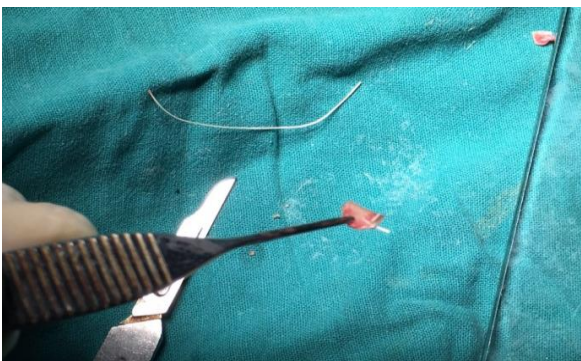

Figure.6 a

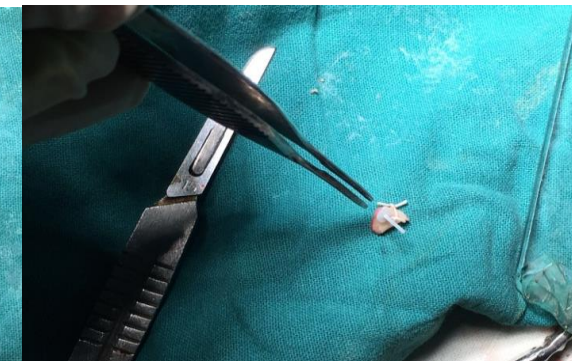


Figure.6 b

Captions for Figures

Figure 1. Showing harvested tragal cartilage with intact perichondrium

Figure 2. Showing reshaped circular tragal cartilage

Figure 3 a & b. Showing vicryl suture being passed through TORP

Figure 4. Showing vicryl suture being passed through TORP & cartilage

Figure 5 a, b, c. Showing vicryl suture, TORP & cartilage assembly from top and side after taking the knot

Figure 6a & b. Showing vicryl suture, TORP & cartilage final assembly

RESULTS

Table 1 Demographic and clinical characteristics of patients in both the groups

Characteristics		PORP	TORP	TOTAL
Age (Years) (Mean)		27.1± 16.5	28.9 ± 12.5	
Male Sex		7 (70%)	8 (80%)	8 (80%)
Type of Hearing Loss	CHL1	2 20.0%	1 10.0%	3 15.0%
	CHL2	3 30.0%	1 10.0%	4 20.0%
	CHL3	4 40.0%	7 70.0%	11 55.0%
	MHL3	1 10.0%	1 10.0%	2 10.0%
Side of Surgery	B/L	1 10.0%	0 0.0%	1 5.0%
	LEFT	7 70.0%	4 40.0%	11 15.0%
	RIGHT	2 20.0%	6 60.0%	8 40.0%
	Malleus (Affected)	6 60.0%	10 100.0%	16 80.0%
Incus (Affected)		9 90.0%	10 100.0%	19 95.0%
Stapes (Affected)		2 20.0%	10 100.0%	12 60.0%

Table 2 Improvement hearing pre and post op in both the groups

	PORP		TORP	
	Pre Op	Post Op	Pre Op	Post Op
CHL1	2 20.0%	3 30.0%	1 10.0%	5 50.0%
CHL2	3 30.0%	3 30.0%	1 10.0%	3 30.0%
CHL3	4 40.0%	0 0.0%	7 70.0%	1 10.0%
MHL2	0 0.0%	1 10.0%	0 0.0%	1 10.0%
MHL3	1 10.0%	0 0.0%	1 10.0%	0 0.0%
WNL		3 30.0%		0 0.0%

Characteristics		PORP	TORP	TOTAL
Hearing Improvement (Yes) as per patient		9 90.0%	9 90.0%	18 90.0%
Grades of Hearing	No Improvement	2 20.0%	2 20.0%	4 20.0%
	Grade 1	4 40.0%	5 50.0%	9 45.0%
	Grade 2	4 40.0%	3 30.0%	7 35.0%

DISCUSSION

With the evolution of newer surgical techniques and advances in the instrument armamentarium available to the otologist, the hearing outcome of ossiculoplasty has shown a noticeable improvement over recent year. Success in ossiculoplasty depends on case selection, stable technique, post-operative care and patient related co morbidities (8). Ossicular grafts and prostheses must couple well at their ends to bone or soft tissue, but must remain suspended in air elsewhere in order to transmit sound effectively (9). In addition, ossicular implants are prone to resorption from persistent or recurrent infection and extrusion from negative pressure and tubal insufficiency. Mastoid cellularity had a significant effect on the outcome of the surgery. Black found the middle ear mucosa to be a predictor of postoperative hearing outcome (10). He reported his SPITE method of assessment, which divided prognostic factors into surgical, prosthetic, infection, tissue, and Eustachian factors.

The presence of a malleus handle contributed to a successful surgical outcome, but the presence of a stapes suprastructure did not significantly affect the outcome of the surgery (9). When the malleus handle was present, PORP and Incus gave better results than TORP. When the malleus handle was eroded, the results were superior when the stapes suprastructure was also involved and TORP was used as an ossicular replacement material than when the stapes suprastructure was present (9,10). Theoretically, the stapes superstructure should

contribute little or nothing to the acoustic gain of the middle ear mechanism, whereas in fact the malleus actually may be significant acoustically through its action as a catenary lever and impedance matcher (9).

The type of mastoidectomy also proves to be an important factor affecting hearing results. Canal wall down cases providing poorer results as compared with intact wall mastoidectomy. One would expect poorer hearing results in a canal-wall-down situation because a shallow middle ear cleft is less acoustically efficient and preservation or reconstruction of the canal wall favours a more physiologic ossiculoplasty, with less chance for contact and fibrosis of the prosthesis to the promontory or facial nerve (11, 12).

Teflon prosthesis is a very versatile and compatible material for ossiculoplasty with less wear and tear and it remains in place for several weeks to allow sufficient time for mucosal regeneration and resists degradation and resorption (13). Literature supports the use of a small piece of cartilage over the prosthesis so as to avoid its contact with the graft thus preventing extrusion. This cartilage cover has the propensity to get displaced during the post-operative period enhancing the extrusion rate with these prosthesis (14,15). Suturing the cartilage with PORP or TORP keeps the assembly in position during the first few weeks till the healing is complete. This period is very critical for displacement of the cartilage over the prosthesis. The vicryl sutures being absorbable in about 2 weeks prevents any long term hazards of foreign body granulomatous

reaction in the middle ear. All this is expected to result in better post-operative hearing outcomes.

CONCLUSION

- Teflon prosthesis is a very versatile and compatible material for ossiculoplasty with less wear and tear and it remains in place for several weeks.
- Suturing the cartilage with PORP or TORP using vicryl suture keeps the assembly in position during the first few weeks till the healing is complete.
- TORP/PORP cartilage assembly with vicryl sutures prevents long term hazards of foreign body granulomatous reaction in the middle ear. As well as there are less chances of prostheses extrusion & expected to result in better post-operative hearing outcomes.

REFERENCES

1. Yung M. Long-term results of ossiculoplasty: reasons for surgical failure: *Otology and Neurotology* 2006; 27: 20–26.
2. Dornhoffer JL, Gardner E. Prognostic factors in ossiculoplasty: a statistical staging system. *Otology and Neurotology* 2001; 22: 299–304.
3. Wehrs RE. The homograft notched incus in tympanoplasty. *Archives of Otolaryngology* 1974; 100: 251–5.
4. Moretz WH Jr. Ossiculoplasty with an intact stapes: superstructure versus footplate prosthesis placement. *Laryngoscope* 1998;108:1–12.
5. Chole RA, Skarada DJ. Middle ear reconstructive techniques. *Otolaryngol Clin North Am* 1999;32:489–503.
6. Brackmann DE, Sheehy JL, Luxford WM. TORPs and PORPs in tympanoplasty: a review of 1042 operations. *Otolaryngol Head Neck Surg* 1984; 92: 32–7.
7. Shea MC. The use of silastic in tympanoplasty surgery. *Clinical Otolaryngology and Allied Sciences* 1981; 6: 125-6.
8. Wright T, Valentine P. The anatomy and embryology of the external and middle ear in: Gleeson M, Browning GG, Burton MJ, Clarke RW, Hibbert J, Jones NS et al. *Scott- Brown's Otorhinolaryngology, Head and Neck Surgery*. 7th Ed. Great Britain: Hodder Arnold. 2008: 3105- 25.
9. S Schavan, P V Jain, J N Vedi et al. *Iranian Journal of Otorhinolaryngology*, Vol.26(3), Serial No.76, Jul 2014.
10. Black B. Ossiculoplasty prognosis: the SPITE method of assessment. *AmJ Otol*. 1992; 13(6): 544-51.
11. Albu S, Babighian G, Trabalzini F. Prognostic factors in tympanoplasty. *AmJ Otol* 1998; 19(2): 136-140.
12. Ars B, Decraemer W, Ars-Piret N. Tympano-ossicular allografts: morphology and physiology. *Am J Otol* 1987; 8: 148- 54.
13. Nguyen DQ, Lavieille JP, Schmerber S. Failure rate and revisionsurgery in ossiculoplasty with Kurz titanium prosthesis. *RevLaryngolOtolRhinol (Bord)*. 2004;125(3):157–162.
14. Ho SY, Battista RA, Wiet RJ. Early results with titanium ossicular implants. *OtolNeurotol*. 2003;24:149–152.
15. Siddiq MA, Raut VV. Early results of titanium ossiculoplasty using the Kurz titanium prosthesis: a UK perspective. *J LaryngolOtol*. 2007;121(6):539–544

How to cite this article:

Nilam U Sathe, Suraj Nair, Dhanashree Chiplunkar, Kamini Chavan *'Porpillage' And 'Torpillage'- Innovative Techniques In Ossicular Reconstruction. Br J Bio Med Res, Vol.06, Issue 01, Pg.1892 - 1888, January - February 2022. ISSN:2456-9739 Cross Ref DOI : <https://doi.org/10.24942/bjbmr.2022.919>*

Source of Support: Nil

Conflict of Interest: None

Your next submission with [British BioMedicine Institute](#) will reach you the below assets

- Quality Editorial service
- Swift Peer Review
- E-prints Service
- Manuscript Podcast for convenient understanding
- Global attainment for your research
- Manuscript accessibility in different formats
(Pdf, E-pub, Full Text)
- Unceasing customer service
- Immediate, unrestricted online access
- Global archiving of articles



Track the below URL for one-step submission

<https://bjbmr.org/manuscript-submission/>